
Section D: Pharmacognosy and Phytochemistry.

Review Article

SCREENING OF PHARMACOLOGICAL ACTIVITIES OF *RHIZOPUS STOLONIFER* (BLACK BREAD MOLD).

Shabana, Samah^{1*}, Shalaby, Mohamed Fouad², Zaki, Alsayed Ahmed², Elhaggar, Radwan Said³

¹ Department of Pharmacognosy and Toxicology, College of Pharmaceutical Sciences and Drug Manufacturing, Misr University for Science and Technology (MUST), 12585, Giza, Egypt.

² Pharmaceutical Sciences Department, Pharmacy Programme, Batterjee Medical College.

³ Department of Pharmaceutical Chemistry, Faculty of Pharmacy, Helwan University.

*Correspondence :samah.shabana@must.edu.eg; Tel.: +2-010- 97006433

Received: 17 December 2023

Accepted: 8 March 2024

Published: 29 March 2024

Editors

Rofida Albash

Mahmoud Eltahan

Keywords

Fungi.

Natural Remedy.

Anti-diabetic.

Natural products.

Rhizopus Stolonifer

Abstract

Fungi play a crucial role in the management of diseases in humans and other animals, making a highly significant contribution. Numerous biologically active compounds derived from fungi have been extensively studied, with these genera serving as sources for hundreds of different compounds. In a particular study, it was reported that the fungus *Rhizopus stolonifer* exhibited antimicrobial activity against selected fungal and bacterial pathogenic strains. This finding sparked interest in investigating other potential activities of this fungus. To conduct the study, *Rhizopus stolonifer* was obtained by incubating twenty hydrated bread at a temperature of 35 °C. The fungal material was then carefully collected and macerated in 70% ethanol for a period of approximately 7 days. The investigation focused on the anti-diabetic and antihypertensive activities of *Rhizopus stolonifer*, using a dose level of 25 mg/kg. The effects were assessed by measuring blood glucose levels with a digital glucometer and monitoring blood pressure with a non-invasive recorder apparatus before and after treatment. The comprehensive study revealed that the ethanolic extract of *Rhizopus stolonifer* significantly reduced blood glucose levels compared to the control group of mice with Alloxan-induced diabetes. However, there were no changes observed in systolic or diastolic blood pressure when compared to the control group of mice with fludrocortisone-induced hypertension. Furthermore, the histopathological examination demonstrated that *Rhizopus stolonifer* exhibited a protective and regenerative effect on beta cells in the pancreas of diabetic mice. Additionally, it displayed a protective effect on the renal tubules tissue in the kidneys of hypertensive mice.

Introduction

Several microorganisms have the capacity to produce bio-compounds. Numerous secondary metabolites derived from fungi have significant commercial value. Fungi naturally synthesize antibiotics to eliminate bacteria, thereby reducing competition in their natural habitat. The primary secondary metabolites are antibiotics, while others include mycotoxins and ergot-alkaloids. Additionally, the commonly used immune-suppressant cyclosporine acts as an inhibitor of angiogenesis and a suppressor of tumor growth [1]. These fungal metabolites can serve as key components in the development of bio-herbicides, bio-insecticides, and bio-fungicides [2]. The majority of fungi also contain bioactive metabolites such as phenolic compounds and flavonoids. It is imperative to explore, identify, preserve, and harness the immense potential of fungal diversity for the betterment of humanity and the environment. *Rhizopus stolonifer* plays a crucial role in the decay of various fruits and vegetables and is also the most prevalent and rapidly growing bread mold [3]. The objective of this study is to investigate the diverse pharmacological activities of *Rhizopus stolonifer* and determine whether it has any harmful effects on different organs.

Material & methods

Fungal materials

The fungal strains purchased from Faculty of science KAU, Jeddah, Saudi Arabia were cultivated on moistened, newly baked bread (20 units) and incubated at a temperature of 45 °C for approximately seven days. The strains were then examined and identified using a microscope, and subsequently scraped to obtain three grams of fungal material. Lactophenol blue stain was used for the microscopic examination, and the colony's color, texture, and size were noted. A single droplet of the stain was applied to a grease-free, spotless slide. To prevent bubbles, a tiny amount of the fungal culture was emulsified on the slide and covered with a coverslip. After that, the slide was examined under a microscope. The observed cultural traits were contrasted with those found in Hartman and Rhode's color atlas (1980).

Preparation of Ethanolic extract

Three grams of fungal material were macerated for approximately seven days in one liter of 70% ethanol to create ethanolic extract. After filtering, the macerated material was dried off in a rotary evaporator with low pressure. The vacuum-dried ethanolic extract was weighted and dissolved in a certain volume of ethanol in water to achieve a concentration of 10 mg/ml following its evaporation in vacuum. The anti-diabetic and antihypertensive properties of the crude extract were measured after it had been diluted with distilled water to a concentration of 1 mg/ml.

Animals

From the animal house at Bhattjee Medical College, 35 adult male mice were utilized. The National Institutes of Health's guidelines for the use and care of laboratory animals were followed in the conduct of the study. The local regulatory body granted its ethical approval for all experimental methods and animal care. The animals were kept in normal cages with a 12/12-hour light/dark cycle, room ambient temperature (22°–25°C), and humidity (45–50%). They were given regular rat feed and unrestricted access to water.

Experimental Diabetes Induction

For two days in a row, intraperitoneal injections (IP) of 100 mg/kg of alloxan (Sigma Aldrich, St Louis, MO, USA) dissolved in normal saline were used to induce diabetes. Following 72 hours, an advanced glucometer was used to monitor blood glucose by taking a sample from the tail vein. Animals classified as diabetics had serum glucose levels greater than 200 mg/dL, whereas normal, non-diabetic animals had levels between 108 and 137 mg/dL [4].

Mineralocorticoid induced hypertension

Mice were maintained on diets high in sodium chloride, and 2% sodium chloride solution was used in place of drinking water in each group. They were given fludrocortisone dissolved in sesame oil at a dose of 10 mg/kg once daily for three weeks after they reached a weight of approximately 25 gm. In the current study, mice with a systolic blood pressure of greater than 150 mmHg were designated as hypertensive mice [5].

Experimental design

The mice were split into the following five groups at random:

Group I: The standard control group for four weeks, five mice received an injection of the same volume of normal saline IP as the vehicle used in the diabetic group.

Group II: (Control group for diabetes) Fasted for the entire night Five mice were given a single intraperitoneal injection of 100 mg/kg Alloxan.

Group III (Diabetic+ *Rhizopus* extract, 25 mg/kg): Five mice were given a single intraperitoneal injection of 100 mg/kg of Alloxan, followed by a daily dose of 25 mg/kg of *rhizopus* extract. IP for four weeks

Group IV (Diabetic+ *Rhizopus* extract, 50 mg/kg): Five mice were given a single intraperitoneal injection of 100 mg/kg of Alloxan, followed by daily administration of 50 mg/kg of *rhizopus* extract. IP for four weeks

Group V: Five mice (hypertensive control)

Determination of blood glucose level

Blood glucose levels were measured at day zero, day one, day seven, day fourteen, and day twenty-one of the experiment. The animals that were fasting had their tails used to draw blood samples. One millimeter of the tail's end was cut, and a drop of blood was used for a blood glucose test using an advanced glucometer (Roche, USA). The tail was then embedded in a 45 °C water bath. The O-toluidine method was used to verify the glucometer's accuracy [6].

Blood pressure recording

With the use of non-invasive blood pressure recorder equipment (Ugo basile instruments, Varese, Italy), basal blood pressure and heart rates were determined. After each rat was put in its restraint, a suitable cuff with a sensor was attached to its tail and the temperature was raised to between 33 and 35 °C. Systolic blood pressure, heart rate, and diastolic blood pressure were all directly measured by the tail cuff and pulse sensor after it was inflated to a pressure greater than 200 mmHg [7].

Biochemicals

Table 1: Effect of *Rhizopus st.* extract on blood glucose level of alloxan-induced diabetic mice

Groups	Mean BGL mg/dl				
	0 day (base line)	1 st day (after 72 hours)	7 th day	14 th day	21 th day
Normal control	118 ± 12	112 ± 11	109 ± 11	111 ± 10	114 ± 12
Diabetic Control (Alloxan + Normal saline; 10ml/kg/d)	112 ± 11	386 ± 23*	331 ± 20*	369 ± 31*	378 ± 35*
Diabetic Test (Alloxan + <i>Rhizopus st.</i> ; 25 mg/kg/d)	103 ± 10	367 ± 34*	314 ± 29*	211 ± 20 ^a	312 ± 31 ^a
Diabetic Test (Alloxan + <i>Rhizopus st.</i> ; 50 mg/kg/d)	110 ± 8.4	353 ± 2.37*	258 ± 21 ^a	208 ± 22 ^a	289 ± 21 ^a

Values are expressed as Mean ± SEM; n=5 mouse in each group. One-way ANOVA followed by Dunnett's multiple comparison test was done. * p<0.05 when compared to Normal Control Group. ^a p<0.05 when compared to Diabetic Control Group.

Every mouse had a blood sample extracted from the retro orbital venous plexus. Centrifugation was used to separate the serum for 10 minutes at 5000 rpm. For biochemical testing, the separated serum was stored at -20 degrees Celsius. Serum creatinine was estimated [8] and urea was measured [9] using a modified urease-Berthgot method to assess kidney function. Alanine aminotransferase (ALT) activation [10] and serum albumin estimation levels [11] were used to assess liver function. Using a spectrophotometer (Shimadzu, model AA200, Tokyo,

Japan), serum samples were analyzed for total protein using the Biuret method, creatinine (CRT) using the Jaff e method, blood urea nitrogen (BUN) using the modified urease-Berthelot method, and alkaline phosphatase (ALP) activity using the enzymatic (International Federation of Clinical Chemistry and Laboratory Medicine) method.

Histopathological assessment for renal injury

Kidneys were promptly removed and fixed in 10% buffered neutral formalin for 48 hours in order to prepare them for optical microscopy. Following a series of alcohol dehydration steps, the fixed organs were cleaned in xylene, embedded in paraffin wax, and sectioned into 4–5 μm thick pieces using a rotary microtome before being stained with hematoxylin and eosin [12]. The fixed kidneys were dehydrated in grades of ethanol (70%, 80%, 90%, and 100%), in accordance with the Kiernan method [13]. After that, the entire kidney was embedded in heated paraffin and allowed to solidify to create paraffin blocks. Horizontal sections were performed, and slides with a 5 μm thickness that contained paraffin were deparaffinized before being mounted in Xylene and put in a glass or metal

slide holder. Following that, the slides were rehydrated using various grades of 100%, 95%, and 80% ethanol. Subsequently, the slides were placed in deionized water. Hematoxylin dye (Poly Scientific, Bayshore, NY, #s212A; Harris hematoxylin with glacial acetic acid) was used for the staining process. Deionized water and tap water were used as rinses. After being dipped in 12 times (quick) acid ethanol to remove the stain, rinse with tap water. The Eosin staining procedure involved mounting the sample for 30 seconds in Eosin (Poly Scientific, Bayshore, NY; #s176; Eosin Phloxine stain), dehydrating it with 95% and 100% ethanol, and then mounting it in xylene. Subsequently, Permount (Fisher Scientific #SP15-100; Histological mounting medium) was used to cover the slides.

Histological Effects of *Rhizopus* on the pancreas

Five mice per group were anesthetized with ether and sacrificed four weeks after the experiment began. A blood sample was taken, the pancreas was removed, and the abdominal cavity was opened. To prepare the pancreases for hematoxylin and eosin (H&E) staining, 10% formalin was applied to each group.

Statistical analysis

For each group of animals, the data were presented as mean ± standard deviation for four animals. After obtaining mean values through one-way analysis of variance (ANOVA), students were tested using the SPSS computer software version 7.5. It was established how significant the differences were both within and between

Table 2: Effect of *Rhizopus st.* extract on systolic BP of hypertensive mice on continuous therapy for 21 days

Hypertensive mice (SBP ± SEM)				
Treatment	Days			
	0	7	14	21
Normal control	112.50±14	110.83±12	90.50±8.5	112.30±11
Hypertensive control	145.16±13*	149.83±14*	153.40±14*	166.11±13*
<i>Rhizopus st.</i> 25mg/kg	143.50±13*	152.40±18*	151.20±14*	157.90±11*
<i>Rhizopus st.</i> 50mg/kg	146.10±13*	153.20±11*	161.40±11*	153.26±12*

SBP: Systolic Blood Pressure, All values are mean of 5 observations + SE, *P<0.05 compared to Normal control group

Table 3: Effect of *Rhizopus st.* extract on kidney and liver functions tests

GPs	Urea (mg/dl)	Creatinine (mg/dl)	Albumin (g/l)	ALT (IU/ml)
Normal control	12.20±1.3	1.34±0.1	50.28±4.3	37.32±4.1
Diabetic control mice	34.51±2.4*	1.97±0.2*	54.13±4.6	41.32±4.4
Hypertensive control mice	60.65±5.7*	2.74±0.3*	45.12±4.1	46.13±5.3
Diabetic mice treated with <i>Rhizopus</i> extract (50 mg/kg)	16.91±1.2 ^a	1.29±0.1 ^a	56.76±4.2	44.54±3.5
Hypertensive mice treated with <i>Rhizopus</i> extract (50mg/kg)	45.96±3.9 ^b	1.93±0.2 ^b	48.38±4.9	43.21±3.1

All values are mean of 5 observations + SE, *P<0.05 compared to Normal control group. ^ap<0.05 when compared to diabetic control group. ^bp<0.05 when compared to hypertensive control group.

the various groups. When p<0.05, the values were deemed significant.

Results

Effect of Aqueous Extracts on blood glucose level

When compared to the Normal control group, the blood glucose level of the Diabetic control group increased significantly ($p < 0.05$). Following multiple administrations of the *Rhizopus* extracts, there was a noteworthy ($p < 0.05$) reduction in blood glucose levels over time at doses of 15, 25, and 25 mg/kg when compared to the group with diabetes. Following three weeks of consumption, *Rhizopus* (50 mg/kg) exhibited a significantly higher hypoglycemic activity ($p < 0.05$) compared to those treated with *Rhizopus* at a dose of 25 mg/kg (Table 1) (Figure 1).

Effect of Aqueous Extracts on blood pressure

After three weeks of treatment, oral fludrocortisone given once daily resulted in a marked increase in blood pressure. When compared to hypertensive control mice, daily oral administration of the two different doses (25, 50 mg/kg) of *Rhizopus* extract did not significantly alter the mice's blood pressure level (Table 2) (Figure 2).

Effect of Aqueous Extracts on Liver & kidney Function Biomarkers

Two biochemical markers that are typically used for assessing liver injury in its early stages are albumin and ALT. While two biochemical markers commonly used to

evaluate kidney function are urea and creatinine. The diabetic control group's plasma albumin and ALT did not differ significantly ($p>0.05$) from the control group. Furthermore, no *Rhizopus* extract-treated group's albumin or ALT change rate was statistically different from the diabetic control group. The groups with diabetes and hypertension had significantly higher levels of creatinine and urea than the normal control group ($p>0.05$). When compared to the diabetic and hypertensive control group, its rate dropped significantly ($p>0.05$) in all *Rhizopus* treatment groups. When compared to diabetic and hypertensive control mice, *rhizopus* extract treatment resulted in a significant ($p>0.05$) drop in the serum levels of urea and creatinine (Table 3).

Histopathological Evaluation

A pancreatic histopathological assessment was done for each group. The Langerhans islet's typical structure is depicted in (Figure 3) in the pancreatic tissue of the normal control group. (Figure 4) illustrates how, in comparison to the normal group, alloxan caused significant alterations in one of the Langerhans islets inside the pancreatic tissue as well as severe necrosis changes. Conversely, when compared to the alloxan-untreated group, the pancreases of the mice in the *Rhizopus* extracts-treated group demonstrated a discernible recovery from the pancreas damage caused by alloxan. Mice treated with 50 gm/kg of extract showed notable improvements, including more prominent islet cells and exocrine cells. This suggested that the architecture of the pancreas improved as the extract concentration increased (Figure 5).

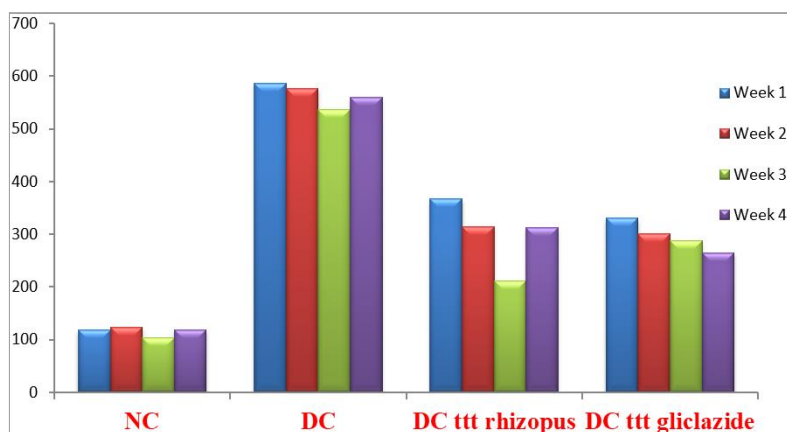


Fig. 1: Effect of ethanolic extract of *Rhizopus stolonifer* on Blood glucose level
Ethanolic extract of *Rhizopus stolonifer* showed a significant decrease in BGL as compared to Alloxan-induced diabetic control mice.

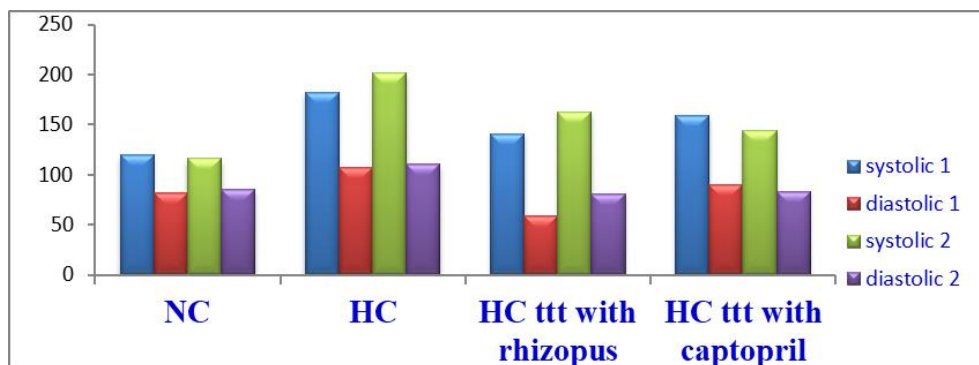


Fig. 2: Effect of ethanolic extract of *Rhizopus stolonifer* on Blood Pressure

Ethanolic extract of *Rhizopus stolonifer* showed a mild decrease or no change in SBP or DBP as compared to fludrocortisones-induced hypertensive control mice.

Normal mouse kidneys have compact tissue appearance and glomeruli (GL). The capillary loops in the glomerulus are delicate and thin. The quantity of mesangial and endothelial cells is normal. The tubules in the vicinity are normal (Figure 6). Untreated hypertensive mice's kidney tissue revealed extensive inflammatory cell infiltration as well as disintegrated cells as a result of cell necrosis (Figure 7). Following treatment with *Rhizopus* extract (25 mg/kg), the tissue architecture of the hypertensive mice significantly improved; more glomeruli were visible, and there were fewer inflammatory cells (Figure 8).

Discussion

There was a moderate reduction in diabetes caused by *rhizopus* extract. This discovery might suggest that *Rhizopus* contained hypoglycemic agents that were concentrated in the aqueous extracts. Histopathology indicates that *Rhizopus* extract promotes regeneration and enhancement of the langerhans islets' beta cells. Its antioxidant effect on beta cells may be the cause of the antidiabetic activity. *Rhizopus* extract protected kidney functions by lowering blood pressure, but it had no effect on blood pressure, serum creatinine and urea levels. A histology study conducted on kidney tissue has confirmed this protection. By reducing edema and thickening the

renal tubules, the extract produced a protective effect on the renal cortex. There is no harmful impact of *rhizopus* extract on liver function. According to Giacco's study [14], hyperglycemia enhanced the production of advanced glycation end products, which in turn promoted the production of free radicals and reactive oxygen species (ROS)—products of malfunctioning endogenous scavengers like catalase and superoxide dismutase (SOD) [14]. The pathophysiology of diabetic nephropathy involves oxidative stress brought on by superoxide anions [14–15]. Fludrocortisone-induced hypertension in mice may be brought on by water and salt retention, which is followed by an increase in blood volume [16]. It has also been demonstrated that aberrant cation turnover results from the changed membrane permeability in the fludrocortisones-salt-treated hypertensive models [17]. Vasoconstriction results from this aberrant cation turnover, which in turn raises arterial blood pressure. Animals with hypertension have higher levels of reactive oxygen species (ROS), and many of them go on to develop end-stage renal disease [18]. Chitin is found in many different types of fungi, including Ascomycetes, Phycmycetes, and Basidiomycetes. It is a part of the cell walls and structural membranes of these organisms as well as mycelia, stalks, and spores. Proteins, glucans, and

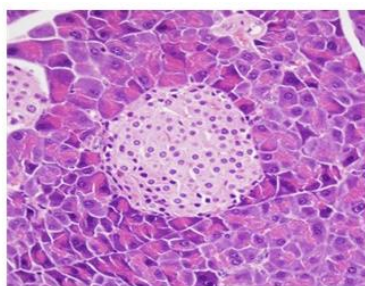


Figure 3: Normal control group showed a normal structure of langerhans islet in the pancreas tissue (Hematoxylin and Eosin x200).

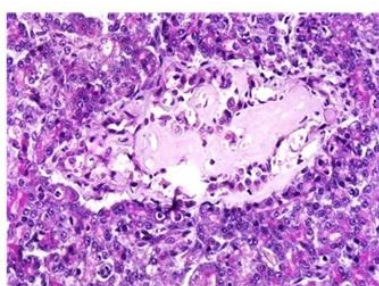


Figure 4: Diabetic control group showed a necrotic part in one of langerhans islets inside the pancreas tissue (Hematoxylin and Eosin x200).

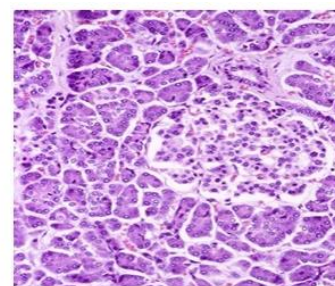


Figure 5: Diabetic group treated with *rhizopus* extract showed a mild protection on beta cells in langerhans islet (Hematoxylin and Eosin x200).

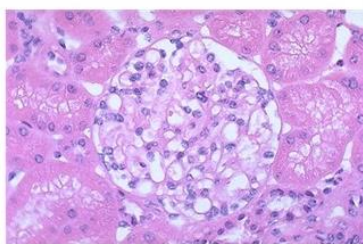


Figure 6: Normal control group showed a normal glomerulus. The glomerular capillary loops are thin and delicate. Endothelial and mesangial cells are normal in number. The surrounding tubules are normal (Hematoxylin and Eosin x200).

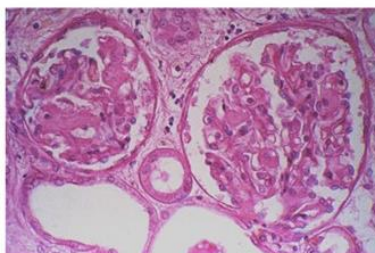


Figure 7: Hypertensive control group showed thickening in the Bowman's capsule and enlargement in proximal renal tubules (Hematoxylin and Eosin x200).

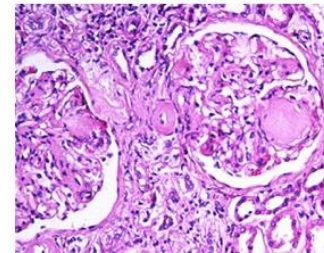


Figure 8: Hypertensive group treated with *rhizopus* extract showed a moderate protection on renal tubules & bowen capsules in renal cortex (Hematoxylin and Eosin x200).

mannans make up the majority of the remaining organic fraction, with amounts ranging from traces to up to 45% [19]. Various rhizopus species yield varying amounts of chitin when isolated [20–21]. One of the most important effects of chitin is its antioxidant property, which is thought to support a variety of activities, including anti-inflammatory, anticoagulant, antitumor and anticancer, antimicrobial, hypocholesterolemic, and antidiabetic effects [22]. Rhizopus st. extract may have a protective effect on kidney and pancreatic tissues because of its chitin-related antioxidant activity. Prior studies have demonstrated that antioxidant supplementation decreased renal damage in diabetic rats [23–24]. When compared to the hypertensive and diabetic control groups, the consumption of Rhizopus st. aqueous extract in the treated hypertensive and diabetic groups resulted in lower serum levels of creatinine and urea. It seems that the Rhizopus st. extract improved the mice's capacity to withstand oxidative stress and fortified their antioxidant system, which decreased the subsequent renal damage.

The results demonstrated that the glucose level, which had risen after the administration of alloxan-induced diabetic mice, could be decreased by the long-term administration of Rhizopus st. extract. Rhizopus extract at the doses examined in the current study (Table 2) did not have any detrimental effects on kidney or liver function, which is an amazing privilege for novel investigational drugs, based on changes in the concentrations of creatinine and urea as well as in liver enzymes. Furthermore, there were no discernible differences between the doses of 15 and 25 mg/kg of the extract in the pattern of changes in the various groups.

The current study demonstrated that renal function was significantly impaired by diabetes and hypertension. When Rhizopus st. extract was administered to hypertensive and diabetic mice, these impairments were significantly reduced or completely cured.

Conflicts of Interest

The authors clarified that there is no conflict of interest in this study.

References

- [1] Zhang H, Wang L, Zheng X, Dong Y: Effect of yeast antagonist with heat treatment on postharvest blue mold decay and Rhizopus decay of peaches. *Int. J. Food Microbiol.*, (2007);11(5): 53-58.
- [2] Srivastava N, Shwarupa, S, Bhagyawant, SS: Comparative study on the anti termite, antimicrobial and antioxidant activity of leaf and root extracts of pathos aurea. *J.Pharm.Res. Clin. Prac.*, (2011);1(2): 25-30.
- [3] Hernández-Lauzardo AN, Bautista-Baños NS, Trejo-Espino JL, Velázquez-del Valle MG: Identification of Rhizopus stolonifer (Ehrenb :Fr.) Vuill: causal agent of Rhizopus rot disease of fruits and vegetables. *Mex. J. Phytopathol.*, (2006); 24: 65-69
- [4] Kanter M, Coskun O, Korkmaz A, Oter S: Effects of Nigella sativa on oxidative stress and betacell damage instreptozotocin-induced diabetic rats. *Anat Rec A Discov Mol Cell Evol Biol.*, (2004); 279 (1):685-91.
- [5] Hensen J, Oelkers W: Mineralocorticoid-induced hypertension. *Med Klin (Munich)*, (1997); 92(5): 273-8.
- [6] Mukherjee KI: Medical laboratory technology. Tata Mc Graw Hill. (1988); 3: 991-993.
- [7] Siddiqui MR, Hussain AA, ASIF RM, ATISH P: Synthesis, characterization and hypertensive activity of some new substituted PYRIDAZINE derivatives. *Journal of the Chilean Chemical Society.* (2011); 56(4): 856-859.
- [8] Siest G, Schiele F, Young DS: Kinetic determination of creatinine. *Interpretation of Clin. Lab. Tests.* (1985); 220-234.
- [9] Batton CJ, Crouch SR.: Spectrophotometer investigation of urea. *Anal Chem.* (1977); 49: 464-469.
- [10] Dumas BT, Watson WA, Biggs HG: Albumin standard and the measurements of serum albumin with bromocresol green. *Clin. Chem. Acta.* (1971); 31: 87.
- [11] Reitman S, Frankel S: A colorimetric determination of serum glutamic oxaloacetic and glutamic pyruvic transaminase. *Am. J. Clin. Path.* (1957); 28:56-58.
- [12] Luna LG: Manual of Histologic Staining Methods of the Armed Forces Institute of Pathology. 3rd edn. New York. 1968.; McGraw-Hill Book Company
- [13] Kiernan JA: Histological and histochemical methods: theory and practice. 3rd ed. London, New York & New Delhi. (2001); Arnold Publisher: 111-162
- [14] Giacco F, Brownlee M: Oxidative stress and diabetic complications. *Circ Res.* (2010); 107(9):1058-70
- [15] Kaneto H, Katakami N, Kawamori D, Miyatsuka T, Sakamoto K, Matsuoka TA: Involvement of oxidative stress in the pathogenesis of diabetes. *Anti-oxide Redox Signal.* (2007); 9: 355-66.
- [16] Distler A, Philipp TS, Thiede H: Studies on the Blood Pressure Increasing Mechanism of Mineralocorticoids. *Endocrine Regulation of Electrolyte Balance.* Springer Berlin Heidelberg. (1986): 57-63
- [17] Martin K, Zipser R, Horton R: Effect of prostaglandin inhibition on the hypertensive action of sodium-retaining steroids. *Hypertension.* (1981); 3(5):622-62.
- [18] Manning Jr, Tian N, Meng S: Oxidative Stress and Antioxidant Treatment in Hypertension and the Associated Renal Damage. *Am J Nephrol.* (2005); 25(4):311–317
- [19] Roberts GAF: Chitin Chemistry, 1st ed. MacMillan, London. (1992)
- [20] Motoyama T: Isolation of a class IV chitin synthase gene from a zygomycete fungus, Rhizopus oligosporus. *FEMS Microbiol Lett* . (1998); 169(1):1-8
- [21] Ramanathan A, Kittusamy R: Antihepatotoxic effect of isolated chitin from Rhizopus oryzae against

paracetamol-induced hepatotoxicity. Bangladesh Journal of Pharmacology. (2011); 6(1): 64-70

[22] Ngo DH, Kim SK: Antioxidant effects of chitin, chitosan, and their derivatives. Adv Food Nutr Res. (2014); 73:15-31

[23] Thomson M, Al-Amin ZM, Al-Qattan KK, Shaban LH, Muslim A: Anti-diabetic and hypolipidemic properties of garlic *Allium sativum* in streptozotpcin-induced rats. *Int J Diabetes & Metab*. (2007); 15:108-115.

[24] Zare T, Mokhtari M, Mohammadi J: The Effect of Hydroalcoholic Extracts of *Prangos Ferulacea* on Blood Factors of Kidney and Liver Functions in Diabetic Male Wistar Rats. *Journal of Fasa University of Medical Sciences*. 2012; 2:174-180.